

Prospective Study



# Ultrasonic Osteotome Assisted Full-Endoscopic en Block Resection of Thoracic Ossified Ligamentum Flavum: Technical Note and 2 Years Follow-up

Zhen-zhou Li, MD, Zheng Cao, MD, PhD, Hong-liang Zhao, MD, Wei-lin Shang, MD, and Shu-xun Hou, MD

From: Department of Orthopedic Surgery, the Fourth Medical Center of Chinese PLA General Hospital, Beijing, China

Address Correspondence: Zhen-zhou Li, MD  
Chief Surgeon  
Department of Orthopedic Surgery, The Fourth Medical Center of Chinese PLA General Hospital,  
No. 51, Fucheng Road, Haidian District, Beijing 100048, China  
E-mail: dr\_lizhenzhou@163.com

Disclaimer: There was no external funding in the preparation of this manuscript.

Conflict of interest: Each author certifies that he or she, or a member of his or her immediate family, has no commercial association (i.e., consultancies, stock ownership, equity interest, patent/licensing arrangements, etc.) that might pose a conflict of interest in connection with the submitted manuscript.

Manuscript received: 04-03-2020  
Accepted for publication: 09-01-2020

Free full manuscript:  
[www.painphysicianjournal.com](http://www.painphysicianjournal.com)

**Background:** Conventional open laminectomy is considered to be the standard procedure for the treatment of thoracic ossified ligamentum flavum, but multi-segment thoracic laminectomy extensively removes the facet joints and ligamentous tissue, destroying the thoracic spine biomechanics and stability, may lead to delayed thoracic spine kyphosis deformities, which in turn can lead to potential neurological deterioration and local intractable pain.

**Objective:** To introduce the technical notes and clinical outcome of ultrasonic osteotome assisted full-endoscopic en block resection of thoracic ossified ligamentum flavum.

**Study Design:** A prospective cohort study.

**Setting:** Hospital and outpatient surgery center.

**Methods:** From January 2017 to March 2018, 15 patients with 1 – 2 segment thoracic ossified ligamentum flavum were treated with ultrasonic osteotome assisted full-endoscopic en block resection of thoracic ossified ligamentum flavum under local anesthesia. The magnetic resonance imaging and computed tomography of the thoracic spine was reexamined after the operation to evaluate the completeness of ossified ligamentum flavum resection and spinal cord decompression. The patients were followed up on the visual analog scale of back pain and radicular pain, Nurick score and mJOA score of neurological function, and Oswestry Disability Index at 1 week, 3 months, 6 months, one year, and 2 years after operation.

**Results:** All operations of 17 segments thoracic ossified ligamentum flavum in 15 patients were successfully completed without intraoperative conversion to open surgery. There were no intraoperative spinal cord injuries, dura tears, postoperative cerebrospinal fluid leakage, postoperative infections, and postoperative spinal cord injury aggravated symptoms. Postoperative thoracic spine magnetic resonance imaging and computed tomography examinations of all patients showed that the spinal cord was fully decompressed without any residual pressure. Back pain and radicular pain were relieved significantly, and spinal cord function (Nurick, mJOA, and Oswestry Disability Index scores) was obviously restored. The mJOA recovery rate at the 2-year follow-up was 78.3% in average.

**Limitations:** This is an observational cohort study with relative small sample and short-term follow-up.

**Conclusions:** Ultrasonic assisted full-endoscopic en block resection of ossified ligamentum flavum is a safe and effective minimally invasive spine surgery for thoracic myelopathy caused by thoracic ossified ligamentum flavum.

**Key words:** Thoracic myelopathy, ossified ligamentum flavum, full-endoscopic decompression, ultrasonic osteotome, minimally invasive surgery

**Pain Physician 2021: 24:E239-E248**

Conventional open laminectomy is considered to be the standard procedure for the treatment of thoracic ossified ligamentum flavum (TOLF) (1-6), but multi-segment thoracic laminectomy extensively removes the facet joints and ligamentous tissue, destroying the thoracic spine biomechanics and stability, may lead to delayed thoracic spine kyphosis deformities (4,7,8), which in turn lead to potential neurological deterioration and local intractable pain, so more and more doctors tend to use assisted pedicle screw system fixation and fusion surgery (4,9). For 1 – 2 segments of TOLF, some doctors began to use minimally invasive spinal surgery to achieve good results. Using an expandable tubular retractor, combined with a microscope or microendoscopic device, through continuous re-adjustment during surgery, tilting and manipulating the tubular retractor and microscope, extensive exposure of the spinal canal can be achieved while avoiding excessive destruction of facet joints is beneficial to segmental stability of the surgical site and avoids assisted fixation and fusion surgery (10-12). Full-endoscopic TOLF resection has also been reported in small numbers (13-17). Because the full-endoscopic surgical equipment and techniques better integrate the key elements of surgery, including the illumination of the surgical field, the visualization of the field of vision and the precise operation of the surgical instruments, so the use of this technique will further minimize the iatrogenic injuries in the surgery of TOLF resection (13,18). The currently reported full-endoscopic thoracic spinal canal decompression techniques mostly use high-speed burr or manual bone cutting tools such as trephine, Kerrison rongeur, etc. to encroach on TOLF, which often directly produces spinal cord compression in the most severe parts. The mechanical stimulation of the spinal cord may lead to aggravated spinal cord injury; it may also cause incomplete resection of the TOLF, resulting in insufficient decompression of the spinal cord, which will affect the recovery of the spinal cord function after surgery (14,16,17). Ultrasound osteotome is the safest bone cutting tool. During operation, it does not rotate, bounce, or roll, does not entangle the surrounding soft tissue, and the bone structure is selectively removed without injury to surrounding nerve tissue (19-22). Li et al (23) have reported full-endoscopic use of ultrasonic osteotome for thoracic hard discectomy, and excellent safety and surgical outcomes have been obtained. For TOLF, we used full-endoscopic ultrasonic osteotome to perform en block resection of TOLF, which guarantees the safety and thoroughness of TOLF resection under full-endoscope. This study will detail the technical note

of ultrasonic osteotome assisted full-endoscopic en block resection of TOLF and the results of the 2-year follow-up.

## METHODS

### Patients

Fifteen patients who met the inclusion criteria were treated with full-endoscopic en block resection of TOLF between January 2017 and March 2018 in our department.

Inclusion criteria: 1) symptoms, signs, and imaging findings are completely consistent; 2) preoperative computed tomography (CT) shows 1 – 2 segments of TOLF; 3) preoperative CT do not show signs of dura ossification, such as tram track signs, comma signs (24), cowin signs (25), etc.; 4) unilateral or bilateral OLF.

Exclusion criteria: 1) symptoms, signs, and imaging findings are inconsistent; 2) preoperative CT scan showed signs of dura ossification; 3) more than 2 segments of multi-segment TOLF; 4) skin and soft tissue infections in the surgical area; 5) uncorrected coagulopathy; 6) hearing or mental disorders not allowing the patient to effectively communicate with the surgeon and maintain stable position; 7) unable to maintain the prone position to the end of surgery.

### Interventions

Approval to conduct the study was granted by the Ethics Committees of The Fourth Medical Center of Chinese PLA General Hospital. Institutional Review Board approved, informed consent and protocols were provided to all the patients, which described details of the surgery including the mechanism of treatment, predictive outcome, potential risks, and side effects.

### Surgical Procedures

A patient with T10-11 fused type (Sato classification (26,27)) bilateral TOLF (Fig. 1) was selected as an example to introduce the technical notes of full-endoscopic en block resection of bilateral TOLF through a unilateral interlaminar approach (Fig. 2).

The patient was placed in a prone position. G-arm x-ray fluoroscopy was used to determine the lesion segment, and the needle insertion point and the puncture direction were determined according to the preoperative surgical plan. Local anesthesia (0.5% lidocaine) was used. Percutaneous puncture under the G-arm x-ray fluoroscopy monitoring to the left dorsal side of the T10 lamina was performed and then the soft tissue dilator and working sheath was inserted. A full-endoscopic

high-speed burr was used to quickly remove the base of T10 spinous process, the gap between the base of the spinous process and OLF was exposed (Fig. 3A). Full-endoscopic high-speed burr and ultrasonic osteotome (XD880A Ultrasonic Osteotomy Surgical System, SMTP Technology Co., Ltd. China) were used to remove the lower part of the left T10 lamina. The level of the lower edge of the T10 pedicle should be reached on the cephalad side, the lateral part of the inferior articular process should be maintained on the lateral side. The medial edge of the superior articular process of T11 and the OLF were then exposed; the medial half of the left superior articular process of T11 was removed, and the OLF in the left intervertebral foramen was exposed. A full-endoscopic high-speed burr was used to separate the bilateral OLF along the posterior median line of the fused OLF longitudinally, and dissection between the

OLF and deep dura sac was performed with the hook-tip nerve dissector (Fig. 3B). Under full-endoscopic monitoring, the ventral bone of the T10 right lamina was removed with an ultrasonic osteotome, and the decompression buffer space was created on the dorsal side of the right OLF. In this space, the connection of the OLF to the cephalic, caudal, and lateral edges was sequentially cut off (Fig. 3C), so that the right OLF was separated from the surrounding bony structure. The nerve dissector was used to push the OLF backwards to the buffer space, exposing the interval space between the OLF and the deep dura sac, and the tip flexible radiofrequency was used to separate the possible adhesion between the OLF and underlying dura sac (Fig. 3D). The rongeur was used to hold

the OLF and take it out, and the radiofrequency was used to achieve complete hemostasis. The full-endoscopic cut off the bony attachment between the left OLF and the surrounding bone structure in the cephalic, caudal, and lateral sides (Fig. 3E). The left OLF and the deep dura sac were separated by a hook-tip nerve dissector and the left OLF was pulled back (Fig. 3F), bitten with a Kerrison, and removed. Exploration of the thoroughness of the dorsal decompression of the bilateral spinal cord and observation of the free pulsation of the dura sac in the perfused saline was achieved (Fig. 3G). The working sheath and endoscope were withdrawn and the surgical incision was sutured intradermally.

The above-mentioned surgical technique was ac-

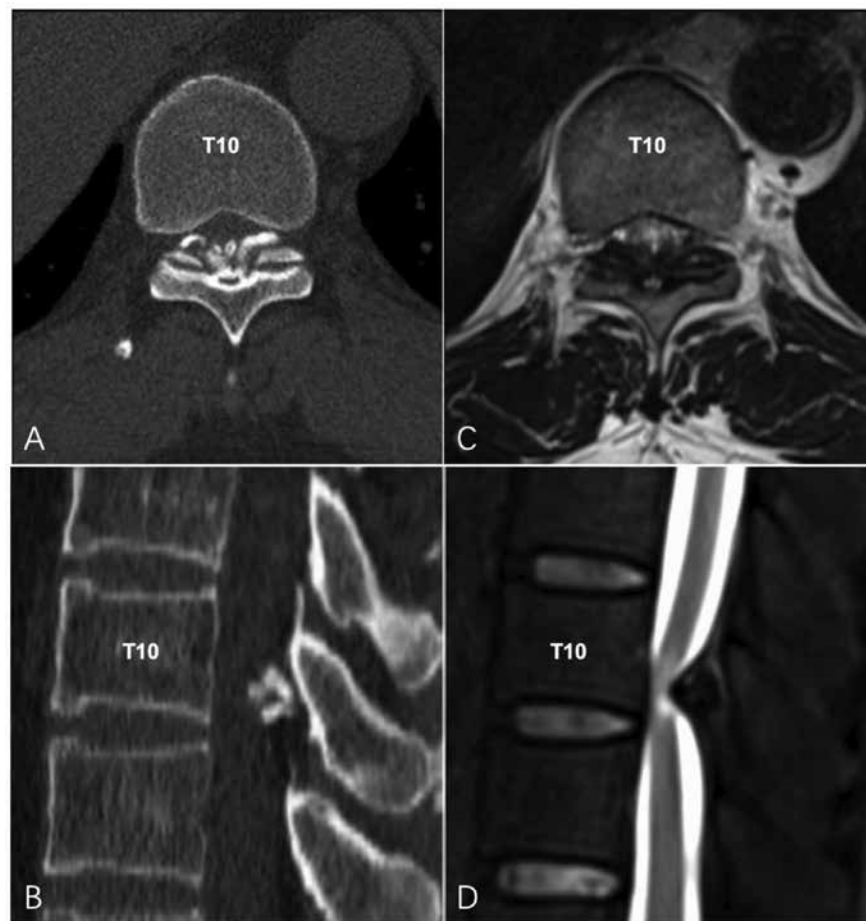


Fig. 1. Preoperative CT and MRI. A. Axial CT scan showed fused type TOLF (Sato classification) at T10-11 level. B. Sagittal CT showed TOLF at T10-11 level severely compression on the spinal cord. C. Axial T2 weighted MRI showed dorsal compression of TOLF on the spinal cord. D. Sagittal FSI T2 weighted MRI showed compressed spinal cord by TOLF from dorsal aspect.

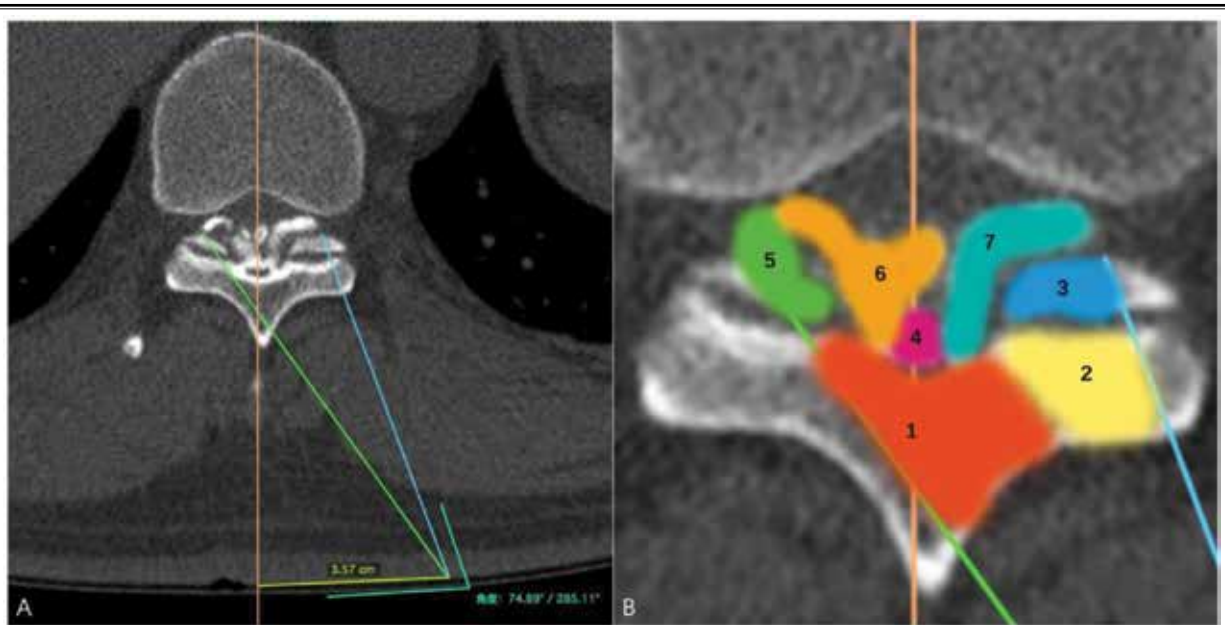


Fig. 2. Surgical planning. A. Planning the surgical incision and surgical path. B. Planning the sequence and process of thoracic spinal decompression. 1-base of spinous process and ipsilateral lamina; 2-ipsilateral inferior articular process; 3-ipsilateral superior articular process; 4-middle fused OLF; 5-contralateral back space dorsal to OLF; 6-contralateral OLF; 7-ipsilateral OLF.

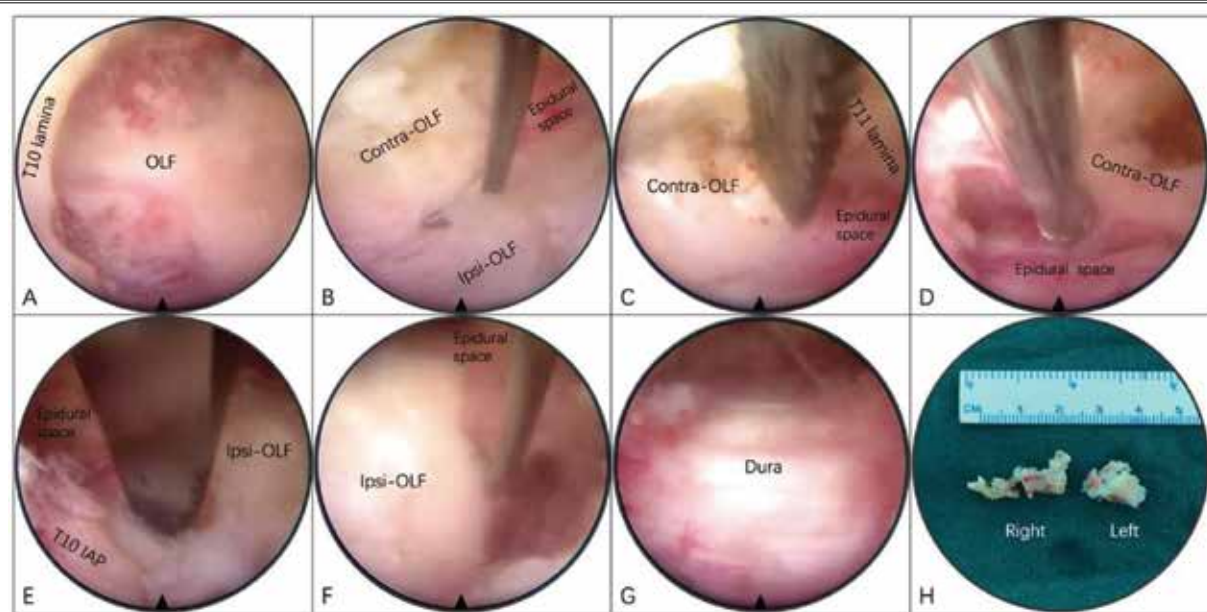


Fig. 3. Ultrasonic osteotome assisted full-endoscopic en block resection of bilateral OLF through unilateral interlaminar approach. A. Full-endoscopic exposure of middle fused OLF. B. Dissection between bilateral OLF and deep dura sac with the hook-tip nerve dissector. C. Connection of the contralateral OLF to the caudal lamina was cut off with ultrasonic osteotome. D. Separation the possible adhesion between the contralateral OLF and underlying dura sac with tip flexible radiofrequency. E. Full-endoscopic cut off the bony attachment between the ipsilateral OLF and the cephalic lamina with ultrasonic osteotome. F. The ipsilateral OLF was separated from the deep dura sac by hook-tip nerve dissector and pulled back. G. Full-endoscopic view of fully decompressed dura. H. En block resected bilateral OLF. The orientation of the endoscopic field of view: upper-right; lower-left; left-cephalad; right-caudal.



tually a combination of full-endoscopic laminotomy (fenestration) through the ipsilateral interlaminar approach and full-endoscopic undercutting OLF resection via the contralateral interlaminar approach. These 2 basic techniques can be used to treat various types of TOLF through individualized combination. For unilateral TOLF, if there is no intervertebral foramen stenosis caused by lateral type TOLF, either of the 2 basic techniques can be chosen; but if intervertebral foramen stenosis is combined, it is best to use the contralateral interlaminar approach for the undercutting resection technique to remove the intracanal TOLF and lateral type TOLF in the intervertebral foramen with the facet joints protected to avoid postoperative instability. For bilateral intracanal TOLF, bilateral laminotomy via a bilateral interlaminar approach or bilateral spinal decompression through an either side unilateral interlaminar approach can be chosen. For those who have bilateral intracanal TOLF combined with unilateral foraminal stenosis, choose the bilateral spinal decompression technique through the unilateral interlaminar approach contralateral to the side of the foraminal stenosis; for bilateral intracanal TOLF with bilateral foraminal stenosis, bilateral undercutting decompression through the bilateral contralateral interlaminar approach can be chosen.

### Outcome Assessment

Thoracic magnetic resonance imaging (MRI) and CT on the second postoperative day was re-examined to assess the adequacy of spinal cord decompression, and 3 months postoperative thoracic MRI was used to further evaluate the adequacy of spinal canal decompression and the expansion of the dura sac (Figs. 4, 5).

The patients were followed up at 1 week, 3 months, 6 months, one year, and 2 years for pain symptom relief and nerve function recovery. Visual analog scale (VAS) was used to evaluate back pain and radicular pain, Nurick score (28) and modified Japan Orthopedics Association (mJOA) score (29) were used to evaluate neurological function, Oswestry Disability Index (ODI) (30) was used for function evaluation of the thoracic spine. The calculation method of mJOA recovery rate (RR) at 2-year postoperative follow-up is as follows:  $RR = (\text{postoperative mJOA} - \text{preoperative mJOA}) / (11 - \text{preoperative mJOA}) \times 100\%$  (29).

### Statistical Analysis

SPSS 26 software (SPSS Inc., Chicago, IL) was used for statistical analysis. One-way analysis of variance (ANOVA) was performed on VAS scores of back pain and radicular pain, Nurick score, mJOA score, and ODI scores before surgery, 2 days, 3 months, 6 months, 1

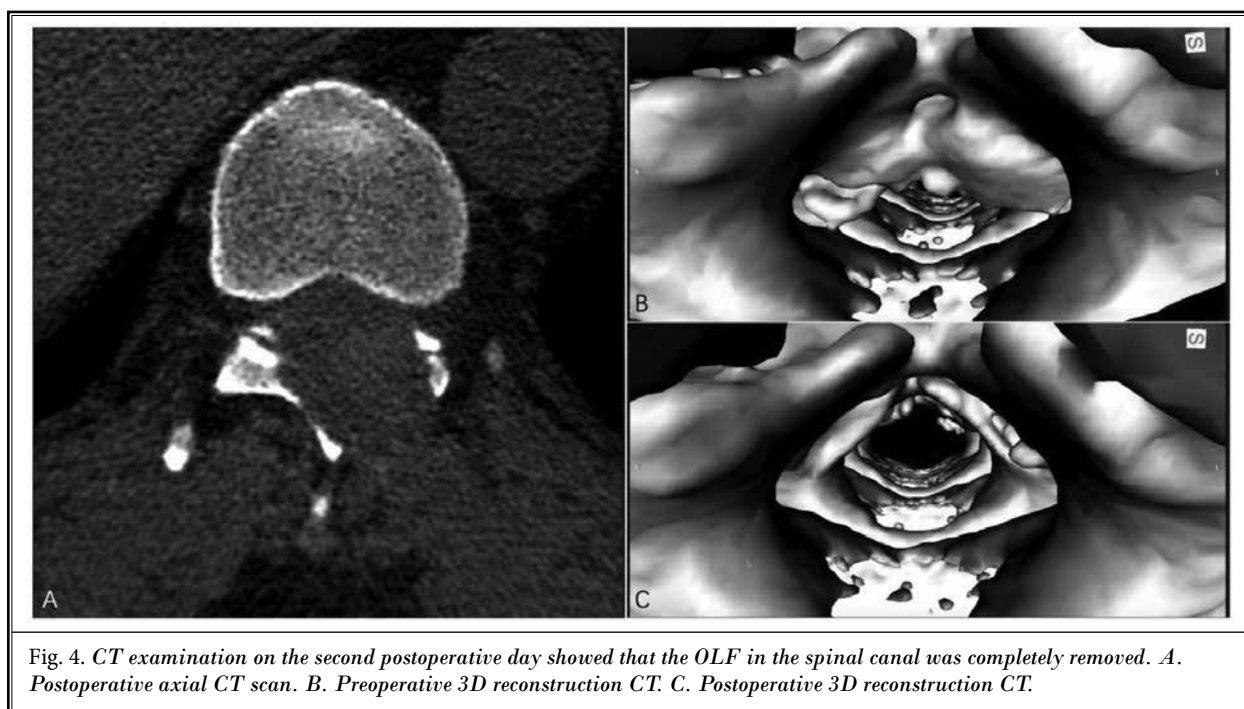


Fig. 4. CT examination on the second postoperative day showed that the OLF in the spinal canal was completely removed. A. Postoperative axial CT scan. B. Preoperative 3D reconstruction CT. C. Postoperative 3D reconstruction CT.

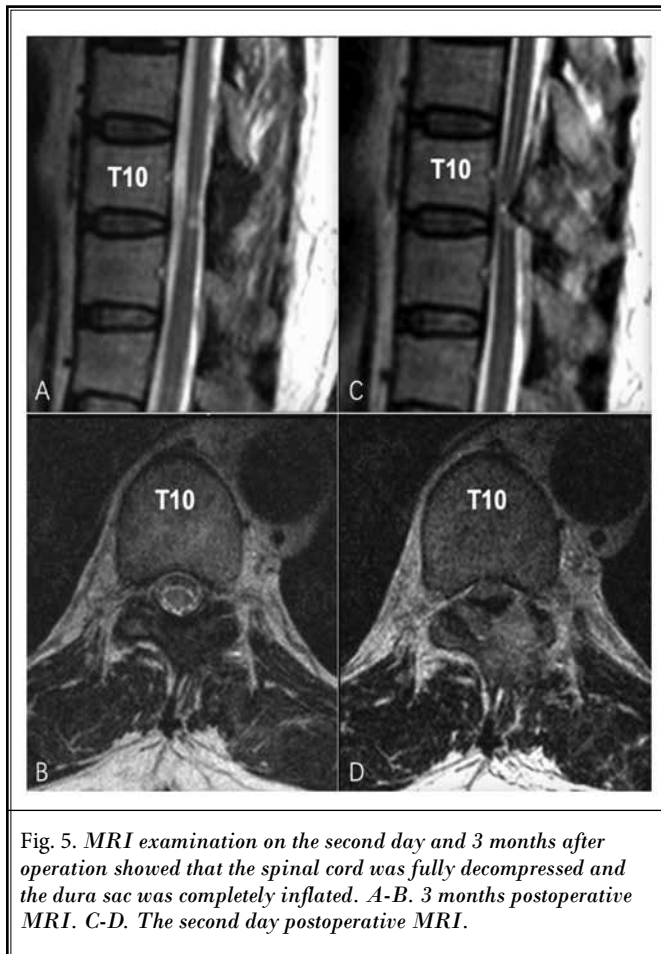


Fig. 5. MRI examination on the second day and 3 months after operation showed that the spinal cord was fully decompressed and the dura sac was completely inflated. A-B. 3 months postoperative MRI. C-D. The second day postoperative MRI.

year, and 2 years after surgery. Multiple comparisons at different time points were performed using the LSD test. A  $P < 0.05$  was considered statistically significant.

## RESULTS

### Patient's Demographic Characteristics

A total of 15 patients with 17 segments of thoracic OLF were included in this study, aged 44 – 78 years (average 56.3 years). There were 11 men and 4 women. The preoperative symptom duration was 2 months to 5 years (average 18.1 months). All patients showed symptoms of thoracic myelopathy, and 8 patients had symptoms of radiculopathy. Preoperative comorbidities included 8 cases of hypertension, 3 cases of diabetes, one case of liver cirrhosis, one case of cardiac function insufficiency, and one case of pulmonary function insufficiency. Lesion segments included: 4 segments at T11-12 level, 7 segments at T10-11 level, 4 segments at T9-10

level, one segment at T8-9 level, and one segment at T3-4 level. Sato classification of the thoracic OLF included one segment of lateral type + extended type, 2 segments of lateral type + enlarged type, one segment of lateral type + fused type, one segment of extended type, 8 segments of enlarged type, 4 segments of fused type, 4 segments of unilateral OLF, and 13 segments of bilateral OLF.

### Postoperative Outcome

All operations were successfully completed under local anesthesia, and no intraoperative conversion to open surgery occurred. The 4 segments of unilateral OLF were full-endoscopic en block resected through the contralateral interlaminar approach (Fig. 6). Twelve segments of bilateral OLF were full-endoscopic bilateral en block resected through the unilateral interlaminar approach. The remaining one segment of bilateral OLF (fused type + bilateral lateral type) was full-endoscopic bilateral en block resected through bilateral contralateral interlaminar approaches (Fig. 7). The operation time was 45 – 180 minutes (average 112.7 minutes), and the intraoperative blood loss (the amount of drainage fluid minus the amount of perfused saline) was 15 – 48 mL (average 24.9 mL). Postoperative thoracic spine MRI and CT examinations of all patients showed that the spinal cord was fully decompressed without any residual pressure. Back pain and radicular pain were relieved significantly, and spinal cord function was obviously restored. There were no intraoperative spinal cord injuries, dura tears, postoperative cerebrospinal fluid leakage, postoperative infections, and postoperative spinal cord injury aggravated symptoms. Complete follow-up data were obtained in all 15 cases (Table 1). The results of all postoperative indices were significantly improved compared with those before surgery, and the difference was statistically significant ( $P < 0.05$ ). Although the VAS scores of back pain and radicular pain at different time points have been further improved, the difference is not statistically significant ( $P > 0.05$ ); however, spinal cord function can be further significantly improved over time within one year after operation. Nurick, mJOA, and ODI scores at one-year follow-up were significantly improved compared with the results at one week and 3 months after surgery ( $P < 0.05$ ), but the results of the 2-year follow-up compared to the results at one-year follow-up were not significantly further improved ( $P > 0.05$ ). The mJOA recovery rate at the 2-year follow-up was 33.3% – 100%, with an average of 78.3%.

## DISCUSSION

The natural course and prognosis of TOLF remain unclear, and patients with myelopathy have achieved good results with operation treatment. The duration of preoperative symptoms and the preoperative severity of myelopathy have been shown to be important factors influencing prognosis. Therefore, it is necessary to select the appropriate surgical timing and surgical methods to treat the thoracic TOLF (3). The RR of mJOA at the 2-year follow-up of 15 patients in this study was as high as 78.3%, which may be related to the preoperative factors such as the short duration of symptoms (average 18.1 months), relatively mild myelopathy (Nurick score less than or equal to 4), and the relatively low severity of TOLF compression of the spinal cord on imaging (without dura ossification and tuberos type of TOLF). The use of ultrasound osteotome assisted full-endoscopic TOLF en block resection technique under local anesthesia was another important reason patients obtained excellent postoperative clinical outcomes and imaging results.

Dural ossification is often seen in the fused and tuberos types cases according to Sato classification, the spinal cord is severely compressed, difficult to treat under full-endoscopic surgery, prone to increased spinal cord injury, postoperative cerebrospinal fluid leakage and other complications (24,25,31), so we recommend conventional open surgery performed to remove the ossified dura mater and OLF, and so OLF combined with dura ossification was included in the contraindication of full-endoscopic TOLF resection.

The surgical technique for decompression of thoracic myelopathy caused by TOLF is highly demanding (32). According to reports, the rate of neurological deterioration after conventional surgery is as high as 8.4% (33). The most severe site of spinal stenosis caused by TOLF is often in the middle level of the facet joint (34). Wang et al (35) found that in the OLF-induced thoracic

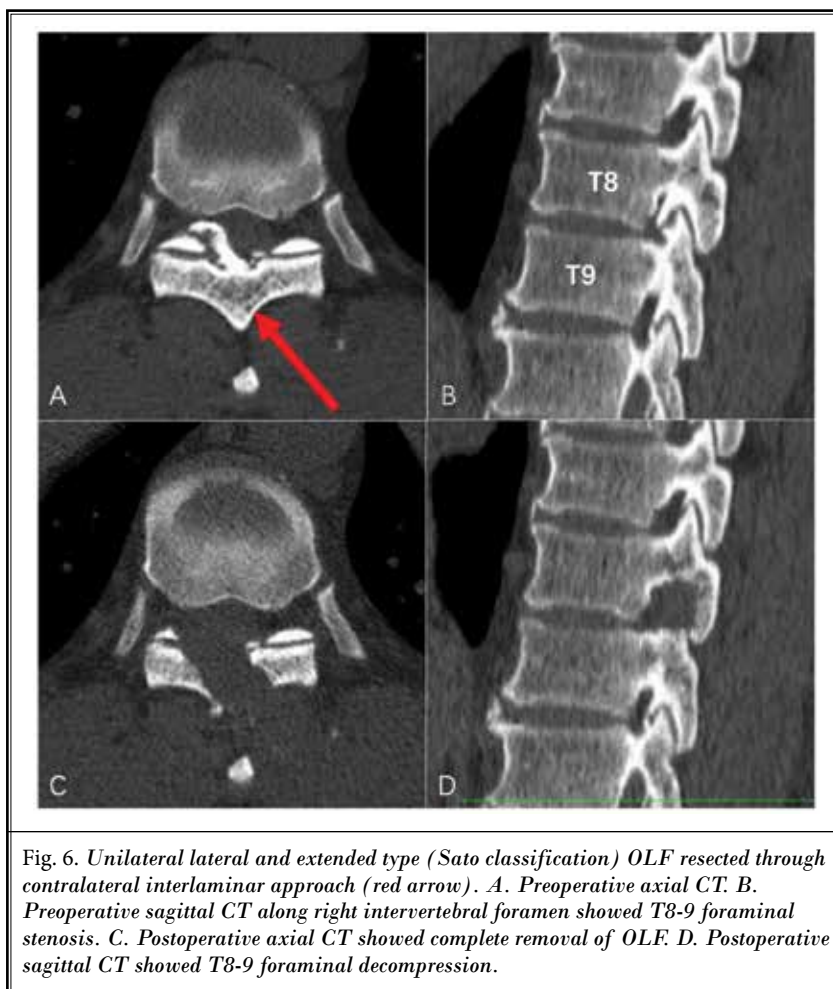


Fig. 6. Unilateral lateral and extended type (Sato classification) OLF resected through contralateral interlaminar approach (red arrow). A. Preoperative axial CT. B. Preoperative sagittal CT along right intervertebral foramen showed T8-9 foraminal stenosis. C. Postoperative axial CT showed complete removal of OLF. D. Postoperative sagittal CT showed T8-9 foraminal decompression.

spondylosis, the most severe stenosis level of the OLF apex is at the level 2.7 mm above the disc level. This part of the OLF tightly compresses the spinal cord, so this level is a key part of surgical decompression. Therefore, Wang et al (35) emphasized the en bloc posterior elevation and resection of OLF plaque with lamina at this level. Any surgical instrument within spinal canal at this level may be associated with an increased risk of irreversible spinal cord injury. For full-endoscopic thoracic decompression, our surgical technique, based on the French-door laminectomy, also emphasizes the en bloc posterior elevation and resection of the OLF at the most severe stenosis levels.

The conventional bone-cutting tools such as high-speed drills and rotating burrs carry a risk of durotomy and neural injury with inappropriate handling (16,36). The ultrasonic osteotome is a new full-endoscopic bone-cutting tool (23). The ultrasonic osteotome utilizes a back

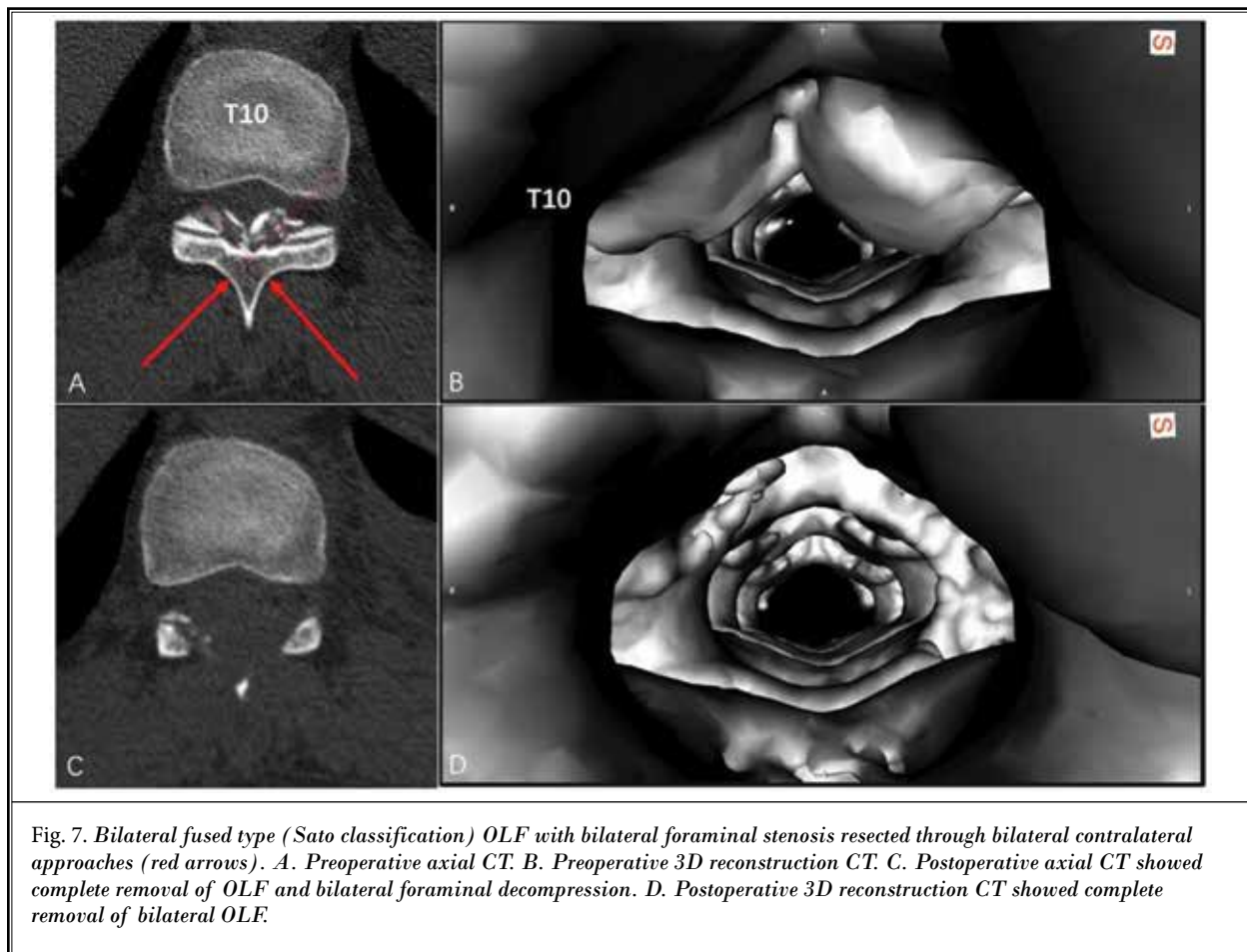


Table 1. Changes of the quantitative indices at various time points after full-endoscopic en block resection of OLF (mean  $\pm$  standard deviation).

Indices	Preoperative	1 week Postoperative	3 months Postoperative	6 months Postoperative	1 year Postoperative	2 years Postoperative	F value
VAS of BP	1.40 $\pm$ 1.81	0.47 $\pm$ 0.52 <sup>a</sup>	0.47 $\pm$ 0.52 <sup>a</sup>	0.47 $\pm$ 0.64 <sup>a</sup>	0.40 $\pm$ 0.63 <sup>a</sup>	0.40 $\pm$ 0.63 <sup>a</sup>	2.784*
VAS of RP	2.80 $\pm$ 2.43	0.53 $\pm$ 0.74 <sup>a</sup>	0.60 $\pm$ 0.83 <sup>a</sup>	0.33 $\pm$ 0.62 <sup>a</sup>	0.33 $\pm$ 0.62 <sup>a</sup>	0.27 $\pm$ 0.46 <sup>a</sup>	10.740*
Nurick score	3.40 $\pm$ 0.63	2.73 $\pm$ 1.03 <sup>a</sup>	1.53 $\pm$ 1.06 <sup>a</sup>	0.87 $\pm$ 0.83 <sup>a</sup>	0.27 $\pm$ 0.46 <sup>ab</sup>	0.20 $\pm$ 0.41 <sup>a</sup>	42.927*
mJOA score	5.87 $\pm$ 1.41	7.27 $\pm$ 1.75 <sup>a</sup>	8.13 $\pm$ 1.19 <sup>a</sup>	8.87 $\pm$ 0.99 <sup>a</sup>	9.67 $\pm$ 0.72 <sup>ab</sup>	9.87 $\pm$ 1.06 <sup>a</sup>	23.094*
ODI	53.73 $\pm$ 12.23	43.80 $\pm$ 14.22 <sup>a</sup>	33.67 $\pm$ 12.84 <sup>a</sup>	27.93 $\pm$ 9.77 <sup>a</sup>	21.47 $\pm$ 6.47 <sup>ab</sup>	21.60 $\pm$ 6.09 <sup>a</sup>	21.693*

\*, ANOVA,  $P < 0.05$ ; a, LSD test,  $P < 0.05$ , compared to Preoperative; b, LSD test,  $P < 0.05$ , compared to 1 week and 3 months Postoperative. BP-back pain; RP-radicular pain.

and forth micromotion rather than rotatory-motion to allow precise removal of bone with minimal impact to the adjacent soft tissues (37). Energy from the cutting edges of these devices is preferentially transmitted to hard structures (bone). Adjacent soft tissues (ligamentum flavum, posterior longitudinal ligament, dura) are spared as these structures can bend, vibrate, and deform

to vibratory micromotion with minimal transmission of energy (38-41). The ultrasonic osteotome has been used for open spinal surgery (21,42-46). However, ultrasonic osteotome is used without direct visualization of the dura in open spine surgery, and spinal cord injury may occur by insertion of the blade beyond the inner cortex of lamina, if penetration of the lamina is not felt. Full-



endoscopic use of an ultrasonic osteotome ensures its tip working under endoscopic monitoring. There was a noticeable absence of bleeding from the cut end of the bone consistent with the ultrasonic application (22,40), therefore, the field of vision under the endoscope can be kept highly clear to ensure the accurate operation of the ultrasonic osteotome. At the same time, during the full-endoscopic surgery performed under local anesthesia, timely patient feedback and timely communication between doctors and patients can further ensure the safety of the operation.

Since full-endoscopic thoracic decompression surgery has a steep learning curve, it is important to emphasize the importance of surgical skill training and surgical experience. Full-endoscopic surgery is more difficult in the thoracic spine than in the lumbar spine because the thoracic canal is smaller than the lumbar spine, which results in a smaller surgical space, a narrower surgical area, and a 2-dimensional view with significantly lower surgical efficiency than open surgery. The incidence of each TOLF type according to Sato classification is usually determined by the number of intervertebral segments involved by OLF (26). In other words, patients with 1 – 2 segment OLF are usually lateral, extended, or enlarged

types. In contrast, those patients with multi-segment OLF tend to behave as fused or tuberosus types. Therefore, based on the current status of full-endoscopic spinal surgery equipment and techniques, it is recommended to be used only for patients with 1 – 2 segment TOLF; for multi-segment thoracic OLF, it is recommended to choose open surgical procedures or multiple, staging full-endoscopic surgical resection.

## LIMITATIONS

Due to the low incidence of 1 – 2 segment TOLF, only 15 patients were included in this study, and the sample size was small; there was no standard control group, and it was just a prospective observational cohort study. Therefore, the efficacy and safety of ultrasonic assisted full-endoscopic en block resection of OLF in the treatment of TOLF have yet to be confirmed by the results of large-scale, multicenter, prospective controlled studies.

## CONCLUSION

Ultrasonic assisted full-endoscopic en block resection of OLF is a safe and effective minimally invasive spine surgery for thoracic myelography caused by TOLF.

## REFERENCES

1. Aizawa T, Sato T, Sasaki H, Kusakabe T, Morozumi N, Kokubun S. Thoracic myelopathy caused by ossification of the ligamentum flavum: Clinical features and surgical results in the Japanese population. *J Neurosurg Spine* 2006; 5:514-519.
2. He S, Hussain N, Li S, Hou T. Clinical and prognostic analysis of ossified ligamentum flavum in a Chinese population. *J Neurosurg Spine* 2005; 3:348-354.
3. Inamasu J, Guio BH. A review of factors predictive of surgical outcome for ossification of the ligamentum flavum of the thoracic spine. *J Neurosurg Spine* 2006; 5:133-139.
4. Li F, Chen Q, Xu K. Surgical treatment of 40 patients with thoracic ossification of the ligamentum flavum. *J Neurosurg Spine* 2006; 4:191-197.
5. Miyakoshi N, Shimada Y, Suzuki T, et al. Factors related to long-term outcome after decompressive surgery for ossification of the ligamentum flavum of the thoracic spine. *J Neurosurg* 2003; 99:251-256.
6. Jia LS, Chen XS, Zhou SY, Shao SY, Zhu W. En bloc resection of lamina and ossified ligamentum flavum in the treatment of thoracic ossification of the ligamentum flavum. *Neurosurgery* 2010; 66:1181-1186.
7. Li KK, Chung OM, Chang YP, So YC. Myelopathy caused by ossification of ligamentum flavum. *Spine* 2002; 27:E308-E312.
8. Okada K, Oka S, Tohge K, Ono K, Yonenobu K, Hosoya T. Thoracic myelopathy caused by ossification of the ligamentum flavum. Clinicopathologic study and surgical treatment. *Spine* 1991; 16:280-287.
9. Seichi A, Nakajima S, Takeshita K, et al. Image-guided resection for thoracic ossification of the ligamentum flavum. *J Neurosurg* 2003; 99:60-63.
10. Wang VY, Kanter AS, Mummaneni PV. Removal of ossified ligamentum flavum via a minimally invasive surgical approach. *Neurosurg Focus* 2008; 25:E7.
11. Baba S, Oshima Y, Iwahori T, Takano Y, Inanami H, Koga H. Microendoscopic posterior decompression for the treatment of thoracic myelopathy caused by ossification of the ligamentum flavum: A technical report. *Eur Spine J* 2016; 25:1912-1919.
12. Zhao W, Shen C, Cai R, et al. Minimally invasive surgery for resection of ossification of the ligamentum flavum in the thoracic spine. *Wideochir Inne Tech Maloinwazyjne* 2017; 12:96-105.
13. Ruetten S, Hahn P, Oezdemir S, et al. Full-endoscopic uniportal decompression in disc herniations and stenosis of the thoracic spine using the interlaminar, extraforaminal, or transthoracic retropleural approach. *J Neurosurg Spine* 2018; 29:157-168.
14. Jia ZQ, He XJ, Zhao LT, Li SQ. Transforaminal endoscopic decompression for thoracic spinal stenosis under local anesthesia. *Eur Spine J* 2018; 27:465-471.
15. Liu L, Li Q, Ao J, Du Q, Xin ZJ, Liao WB. Posterior percutaneous endoscopic technique through bilateral translaminar osseous channels for thoracic spinal stenosis caused by ossification of the ligamentum flavum combined with disk herniation at the T10-11 level: A technical note. *World Neurosurg* 2020;

- 133:135-141.
16. Li X, An B, Gao H, et al. Surgical results and prognostic factors following percutaneous full endoscopic posterior decompression for thoracic myelopathy caused by ossification of the ligamentum flavum. *Sci Rep* 2020; 10:1305.
17. An B, Li XC, Zhou CP, et al. Percutaneous full endoscopic posterior decompression of thoracic myelopathy caused by ossification of the ligamentum flavum. *Eur Spine J* 2019; 28:492-501.
18. Ruetten S, Hahn P, Oezdemir S, Baraliakos X, Godolias G, Komp M. Operation of soft or calcified thoracic disc herniations in the full-endoscopic uniportal extraforaminal technique. *Pain Physician* 2018; 21:E331-E340.
19. Hosseini P, Mundis Jr GM, Eastlack R, Pawelek J, Nguyen S, Akbarnia BA. Is There a role for an ultrasonic bone-cutting device in adult spinal deformity: A safety and reproducibility Study. *Shafa Orthopedic Journal* 2016; 3:e7461.
20. Hazer DB, Yaşar B, Rosberg H-E, Akbaş A. Technical aspects on the use of ultrasonic bone shaver in spine surgery: Experience in 307 patients. *BioMed Research International* 2016; 2016.
21. Bydon M, Macki M, Xu R, Ain MC, Ahn ES, Jallo GI. Spinal decompression in achondroplastic patients using high-speed drill versus ultrasonic bone curette: Technical note and outcomes in 30 cases. *Journal of Pediatric Orthopaedics* 2014; 34:780-786.
22. Al-Mahfoudh R, Qattan E, Ellenbogen JR, Wilby M, Barrett C, Pigott T. Applications of the ultrasonic bone cutter in spinal surgery--our preliminary experience. *Br J Neurosurg* 2014; 28:56-60.
23. Li ZZ, Zhao HL, Cao Z, Shang WL, Hou SX. [Technical notes and clinical efficacy analysis of full-endoscopic thoracic discectomy via transforaminal approach]. *Zhonghua Yi Xue Za Zhi* 2020; 100:279-285.
24. Muthukumar N. Dural ossification in ossification of the ligamentum flavum: A preliminary report. *Spine* 2009; 34:2654-2661.
25. Sun XZ, Chen ZQ, Qi Q, et al. Diagnosis and treatment of ossification of the ligamentum flavum associated with dural ossification: Clinical article. *J Neurosurg Spine* 2011; 15:386-392.
26. Sato T. Choice of operative method for ossification of ligamentum flavum based on CT findings. *Rinsho Seikei Geka* 1996; 31:541-545.
27. Sato T. Surgical treatment for ossification of ligamentum flavum in the thoracic spine and its complications. *Spine Spinal Cord* 1998; 11:505-510.
28. Nurick S. The pathogenesis of the spinal cord disorder associated with cervical spondylosis. *Brain* 1972; 95:87-100.
29. Yoon SH, Kim WH, Chung SB, et al. Clinical analysis of thoracic ossified ligamentum flavum without ventral compressive lesion. *Eur Spine J* 2011; 20:216-223.
30. Fairbank JC, Pynsent PB. The Oswestry Disability Index. *Spine (Phila Pa 1976)* 2000; 25:2940-2952; discussion 2952.
31. Sun X, Sun C, Liu X, et al. The frequency and treatment of dural tears and cerebrospinal fluid leakage in 266 patients with thoracic myelopathy caused by ossification of the ligamentum flavum. *Spine* 2012; 37:E702-E707.
32. Mohindra S, Gupta R, Chhabra R, Gupta SK. Compressive myelopathy due to ossified yellow ligament among South Asians: Analysis of surgical outcome. *Acta Neurochirurgica* 2011; 153:581-587.
33. Liao CC, Chen TY, Jung SM, Chen LR. Surgical experience with symptomatic thoracic ossification of the ligamentum flavum. *J Neurosurg Spine* 2005; 2:34-39.
34. Yang Z, Xue Y, Dai Q, et al. Upper facet joint en bloc resection for the treatment of thoracic myelopathy caused by ossification of the ligamentum flavum. *J Neurosurg Spine* 2013; 19:81-89.
35. Wang T, Du C, Zheng X, Shun Y, Liu X, Kou J. Surgical strategies for thoracic myelopathy due to ossification of ligamentum flavum: A technical note based on radiological type. *Turk Neurosurg* 2018; 28:616-624.
36. Hosono N, Miwa T, Mukai Y, Takenaka S, Makino T, Fuji T. Potential risk of thermal damage to cervical nerve roots by a high-speed drill. *J Bone Joint Surg Br* 2009; 91:1541-1544.
37. Vercellotti T. Technological characteristics and clinical indications of piezoelectric bone surgery. *Minerva Stomatol* 2004; 53:207-214.
38. Hu X, Ohnmeiss DD, Lieberman IH. Use of an ultrasonic osteotome device in spine surgery: Experience from the first 128 patients. *Eur Spine J* 2013; 22:2845-2849.
39. Nickele C, Hanna A, Baskaya MK. Osteotomy for laminoplasty without soft tissue penetration, performed using a harmonic bone scalpel: Instrumentation and technique. *Journal of Neurological Surgery Part A: Central European Neurosurgery* 2013; 74:183-186.
40. Sanborn MR, Balzer J, Gerszten PC, Karausky P, Cheng BC, Welch WC. Safety and efficacy of a novel ultrasonic osteotome device in an ovine model. *J Clin Neurosci* 2011; 18:1528-1533.
41. Schaeren S, Jaquière C, Heberer M, et al. Assessment of nerve damage using a novel ultrasonic device for bone cutting. *Journal of Oral and Maxillofacial Surgery* 2008; 66:593-596.
42. Bydon M, Xu R, Papademetriou K, et al. Safety of spinal decompression using an ultrasonic bone curette compared with a high-speed drill: Outcomes in 337 patients. *J Neurosurg Spine* 2013; 18:627-633.
43. Nakagawa H, Kim SD, Mizuno J, Ohara Y, Ito K. Technical advantages of an ultrasonic bone curette in spinal surgery. *J Neurosurg Spine* 2005; 2:431-435.
44. Ito K, Ishizaka S, Sasaki T, et al. Safe and minimally invasive laminoplasty laminotomy using an ultrasonic bone curette for spinal surgery. *Surgical Neurology* 2009; 72:470-475.
45. Matsuoka H, Itoh Y, Numazawa S, et al. Recapping hemilaminoplasty for spinal surgical disorders using ultrasonic bone curette. *Surgical Neurology International* 2012; 3:70.
46. Nakase H, Matsuda R, Shin Y, Park SY, Sakaki T. The use of ultrasonic bone currettes in spinal surgery. *Acta Neurochirurgica* 2006; 148:207-213.